

Long-term results for total lumbar facet joint replacement in the management of lumbar degenerative spondylolisthesis

Yossi Smorgick, MD,² Yigal Mirovsky, MD,¹ Yizhar Floman, MD,³ Nahshon Rand, MD,³ Michael Millgram, MD,³ and Yoram Anekstein, MD²

¹Department of Orthopedic Surgery, ²Spine Unit, Yitzhak Shamir Medical Center, Zerifin, and Sackler Faculty of Medicine, Tel Aviv University; and ³Israel Spine Center at Assuta Hospital, Tel Aviv, Israel

OBJECTIVE The authors evaluated the long-term clinical outcome of a total posterior arthroplasty system in the surgical treatment of lumbar spinal stenosis with degenerative spondylolisthesis.

METHODS Between June 2006 and July 2007, 10 patients with neurogenic claudication due to spinal stenosis and single-level degenerative spondylolisthesis were enrolled in a nonrandomized prospective clinical study. The patients were evaluated with radiographs and MRI scans, the visual analog scale (VAS) for back and leg pain, the Oswestry Disability Index (ODI), and the SF-36 health survey preoperatively and at 6 weeks, 3 months, 6 months, 1 year, 2 years, 3 years, 7 years, and 11 years postoperatively.

RESULTS The mean VAS score for leg pain dropped from 83.5 before surgery to 13 at 6 weeks and 17 at 11 years after surgery. The mean VAS score for back pain dropped from 56.2 preoperatively to 12.5 at 6 weeks and 14 at 11 years after surgery. The mean ODI score decreased from 49.1 preoperatively to 13.5 at 6 weeks and 16 at 11 years after surgery. MRI at 11 years demonstrated stenosis adjacent to the stabilized segment in one patient. This patient was not symptomatic. The authors did not find evidence of progression of the spondylolisthesis in any of the cases. In one patient, conversion to posterolateral fusion was performed due to an early device malfunction.

CONCLUSIONS The results of this 11-year follow-up study demonstrate that, in patients with spinal stenosis and degenerative spondylolisthesis, decompression and posterior arthroplasty maintain clinical improvement and radiological stability.

<https://thejns.org/doi/abs/10.3171/2019.7.SPINE19150>

KEYWORDS TOPS System; degenerative spondylolisthesis; spinal stenosis; laminectomy; posterior spinal fusion; lumbar; surgical technique

FOR the management of lumbar degenerative spondylolisthesis with spinal stenosis, surgical treatment has better results than nonoperative care.¹⁵ Herkowitz and Kurz, in a randomized prospective study, found that laminectomy with fusion was superior to laminectomy alone.⁸ Two recent randomized controlled trials comparing laminectomy alone to laminectomy with instrumented posterolateral fusion reported conflicting results. The first found that lumbar laminectomy with fusion was associated with a slightly greater but clinically meaningful improvement in physical health–related quality of life than was laminectomy alone in patients with degenerative spondylolisthesis and spinal stenosis at 4 years after sur-

gery. However, the cumulative rate of reoperation was 14% in the fusion group and 34% in the decompression-alone group.⁶ The second study found that, in patients with lumbar spinal stenosis, with or without degenerative spondylolisthesis, laminectomy with fusion did not yield better outcomes at 2 and 5 years than laminectomy alone.⁵

The TOPS System (Premia Spine Ltd.) is a total facet replacement device (Fig. 1). It features a motion-preservation solution for patients undergoing surgery for degenerative spondylolisthesis and lumbar spinal stenosis. It integrates the advantages of fusion, as it restores stability, and a laminectomy, as it preserves motion at the instrumented level.^{14,16} The TOPS apparatus allows wide decompression,

ABBREVIATIONS ODI = Oswestry Disability Index; VAS = visual analog scale.

SUBMITTED February 6, 2019. **ACCEPTED** July 2, 2019.

INCLUDE WHEN CITING Published online October 4, 2019; DOI: 10.3171/2019.7.SPINE19150.



FIG. 1. The TOPS System for total posterior arthroplasty prosthesis (Premia Spine Ltd.).

laminectomy, and bilateral total facetectomy to a radical degree compared with surgical fusion. The device resists translation and shear force and recreates physiological motion. The biomechanical and kinematic behaviors of the device in cadaveric spines have been closely examined.^{10,17}

We have previously reported on the shorter-term follow-up of our first 10 cases,² and now we report on an 11-year prospective follow-up period.

Methods

Between June 2006 and July 2007, 10 patients were enrolled in a nonrandomized prospective clinical study. The study was approved by the local IRB. There were 5 females and 5 males whose mean age was 61.3 years (range 52–69 years). The indication for surgery was neurogenic claudi-

cation of at least 12 weeks' duration due to spinal stenosis with single-level grade 1 L4–5 degenerative spondylolisthesis.

Exclusion criteria included scoliosis of more than 10°; discogenic back pain, disc herniation, isthmic spondylolisthesis, and previous surgery at L3–5 segments; current chemical/alcohol dependency or significant psychosocial disturbance; unremitting pain in any spinal position; more than 3 Waddell signs; current involvement in spinal litigation; or receipt of Workers' compensation. The patients' evaluation included the Oswestry Disability Index (ODI) questionnaire, the SF-36 health survey, and the visual analog scale (VAS) for back and leg pain. The questionnaires were completed preoperatively and postoperatively at 6 weeks, 3 months, 6 months, 1 year, 2 years, 3 years, 7 years, and 11 years. An additional physician (Y.S.), who was not part of the operating team, performed the patients' evaluations. Our postoperative 7-year follow-up outcomes have been reported on previously.² The 11-year postoperative radiographs were assessed by a separate radiologist for device failures, such as screw loosening or breakage. On lateral bending radiographs, more than 3 mm of displacement was considered positive for instability.³ An MR image of the lumbar spine was obtained preoperatively and at 2, 7, and 11 years after surgery. In these images, the degenerative changes at adjacent levels were assessed. We compared the 11-year postoperative outcomes with outcomes measured at the 2- and 7-year follow-up visits.

The surgery was performed at the L4–5 segment, and no intraoperative complications occurred. The estimated surgical blood loss was ≤ 700 ml in each of the 10 cases, while the mean surgical time was 3.17 hours (range 2.5–4 hours). The demographic and surgical characteristics of the study cohort are presented in Table 1. Patients were ambulatory at postoperative day 1 or 2 and went home shortly after that.

Statistical analysis was performed using the SPSS software (version 21.0; IBM Corp.). The paired Student t-test was used to analyze the difference in pre- and postoperative VAS, ODI, and SF-36 scores. The ANOVA test with repeated measures was employed to analyze the differences between scores on the VAS, ODI, and SF-36 at the different follow-up intervals. All statistical tests were performed at a 5% significance level.

Results

In one case there was failure of an implant that happened 12 weeks after the initial surgery. This patient underwent fusion 6 months after the initial surgery and did not complete the 11-year follow-up. All other 9 patients returned for complete follow-up visits at 6 weeks, 3 months, 6 months and at 1, 2, 3, 7, and 11 years.

There was significant improvement in back pain after surgery, and improvement was maintained out to the 11-year follow-up visit. The VAS score for back pain dropped from 56.2 before surgery to 12.5 at 6 weeks ($p < 0.05$) and to 13.7 and 3.6 at the 1-year and 2-year follow-up visits, respectively. The VAS score was 19 at the 7-year follow-up, and it decreased further to 14 at 11 years. The VAS score for leg pain demonstrated improvement, which was

TABLE 1. Patient demographic and surgical data

Patient No.	Sex	Age at Op (yrs)	BMI (kg/m ²)	Op Time (mins)	Estimated Blood Loss (ml)	Level of Surgery
1	Female	55	33.2	195	700	L4–5
2	Male	63	29.2	210	700	L4–5
3	Male	51	26	185	400	L4–5
4	Female	59	28.6	145	500	L4–5
5	Female	61	27.2	185	500	L4–5
6	Male	68	24.5	190	500	L4–5
7	Female	55	40	150	500	L4–5
8	Female	65	26.9	215	600	L4–5
9	Male	63	30.4	240	700	L4–5

maintained over time. The preoperative VAS score for leg pain was 83.5, it decreased further to 13 at the 6-week visit ($p < 0.05$), and even further to 9.2 and 3.6 at the 1-year and 2-year follow-up visits, respectively. The VAS score for leg pain was 8.8 at the 7-year follow-up and rose to 17 at 11 years (Fig. 2).

The ODI score before surgery was 49.1, and it dropped to 13.5 at 6 weeks ($p < 0.05$); to 8.6 at 1 year; to 3.3 and 7.8 at 2 years and 7 years, respectively; and to 16 at 11 years. The SF-36 score was 43.2 before surgery, and it rose to 69.9 at 6 weeks after surgery ($p < 0.05$) and to 80.2 and 82.8 at the 1-year and 2-year follow-up visits, respectively. At the 7-year follow-up, the SF-36 score was 74.8; by 11 years after surgery, the SF-36 score was 70.9 (Fig. 2).

As we published before,² there was a statistically significant difference in all outcome measures between preoperative and all postoperative scores ($p < 0.05$). We did not find any statistically significant difference between the 6-week, 3- and 6-month, and 1-, 2-, 3-, and 7-year postoperative outcome scores and 11-year postoperative outcome scores ($p > 0.05$).

When analyzing the postoperative 11-year follow-up ra-

diographic images, we did not find any evidence of screw loosening, screw breakage, spontaneous fusion, or progression of the spondylolisthesis. Flexion/extension radiographs demonstrated that the TOPS implant was mobile, even 11 years after surgery (Fig. 3). The mean preoperative flexion/extension range of motion was 6.1°, it dropped to 3.6° at 3 months, and rose to 5° and 4.8° degrees at 1 year and 7 years, respectively. The motion mildly decreased at the 11-year follow-up with a mean flexion/extension range of motion 4.5° (Table 2).

The preoperative lumbar spine MRI scans were compared to the postoperative MRI scans obtained at the 2-, 7-, and 11-year follow-up visits (Fig. 4). While we did not observe any case of spinal stenosis or listhesis above the instrumented segment on the 7-year scans, we did note one case of stenosis above the instrumented segment. Five years after the initial surgery, this patient had an L3–4 disc herniation. He was treated with physical therapy and a nonsteroidal antiinflammatory drug and his symptoms resolved. Although MRI showed stenosis, the patient was not experiencing any leg pain.

Progressive disc degeneration, with moderate to severe

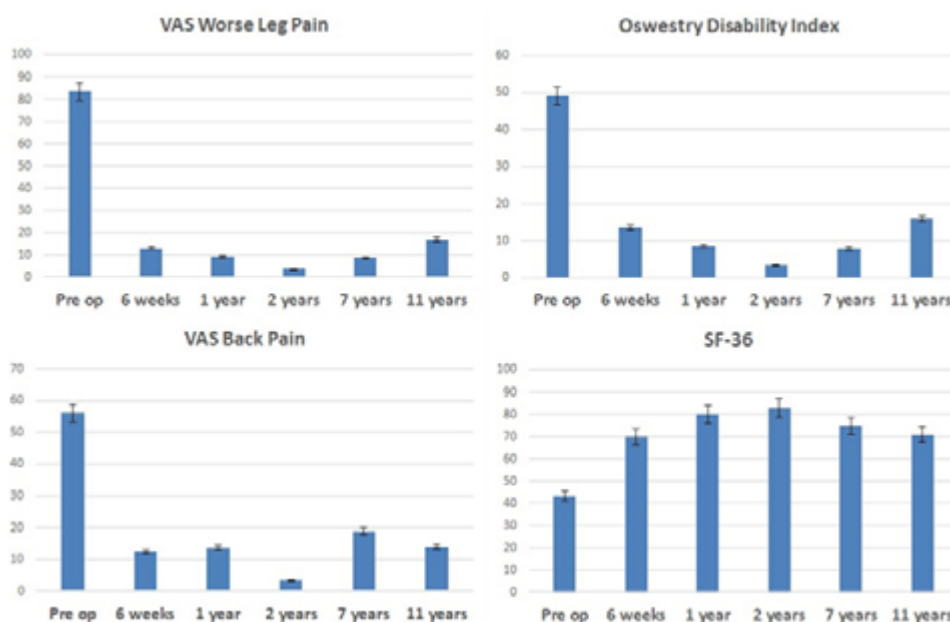


FIG. 2. VAS for leg and back pain, ODI, and SF-36 scores measured at various pre- and postoperative follow-up points.

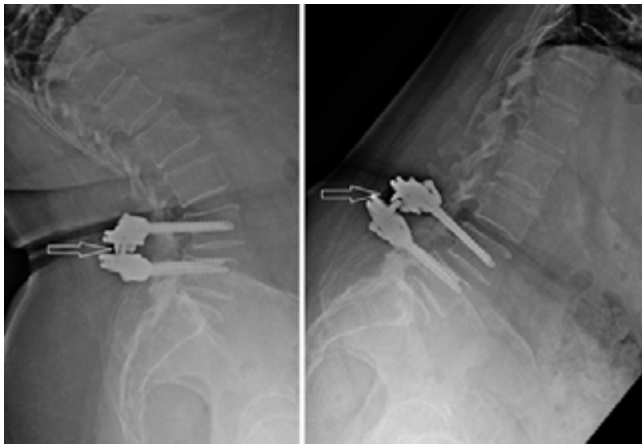

FIG. 3. Flexion and extension lateral radiographs obtained after 11 years of follow-up. We can see that there is motion at the L4–5 segment as the articulating core of the TOPS device moves on flexion and extension images (arrows).

disc degeneration according to the Pfirrmann classification¹¹ at the second, third, or fourth level above the index level, was observed in 4 patients in the 11-year follow-up period compared to 3 patients in the 7-year follow-up period. Retrolisthesis at the second, third, or fourth level above the index level was observed in 5 patients in the 11-year follow-up period. Data regarding the index and adjacent-level disc height as to the overall lumbar lordosis are presented in Table 3.

As noted earlier, there was one case in which an early device failure occurred. Scheduled radiographs at 6 weeks after the index procedure revealed a locked device. It was found that the internal polycarbonate urethane component was damaged, leading to internal locking of the device. During revision fusion surgery, that underwent without complication, and because the screws were found to be solidly anchored to the spine, the TOPS implant was removed and replaced with simple rods. At the last clinic visit prior to surgery, the patient's VAS score for back pain was 40 mm, and the patient did not complain of any leg pain. A minor prosthesis design change provided a solution to this

TABLE 2. Flexion/extension range of motion at the L4–5 segment

Patient No.	L4–5 Flexion/Extension Range of Motion (°)			
	Preop	1 Yr	7 Yrs	11 Yrs
1	10.5	6.5	5	5.3
2	12.4	8.7	8.8	6.7
3	2.6	6.8	4	4.7
4	2	2.4	2.4	4.7
5	3.6	5	2.9	4.5
6	9.8	1.4	3.1	3.6
7	6.1	3.8	5.1	5.1
8	2.8	2.2	1.4	0.3
9	5.2	9	10.4	5.7
Average	6.1	5.08	4.78	4.5

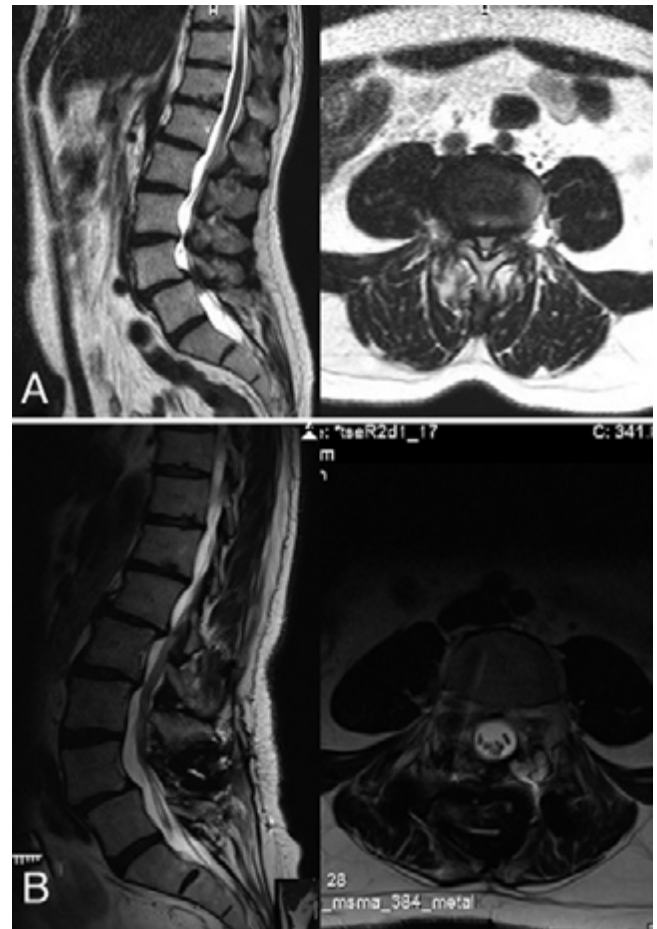


FIG. 4. Sagittal and axial T2-weighted MR images obtained before surgery (A) and at the 11-year follow-up (B).

complication. The effectiveness of this mechanical solution was confirmed by biomechanical tests.

Discussion

This prospective cohort study included 10 patients with lumbar spinal stenosis and degenerative spondylolisthesis, who underwent decompression and posterior arthroplasty with the TOPS System and who were followed for 11 years follow-up. McAfee et al. reported their short follow-up experience with the TOPS System.⁹ Twenty-nine patients with moderate to severe spinal stenosis were enrolled in a prospective clinical trial in which the TOPS device was used. The patients' follow-up ranged from 6 weeks to 1 year. Fifteen of the 29 patients had degenerative spondylolisthesis. The mean 100-mm VAS leg score was 88 mm before surgery, 19 mm at 3 months, and 12 mm at 1 year. The mean ODI score was 57 at baseline. It dropped to 20 and 16 at the 6-month and 1-year follow-up, respectively. No cases of slip progression were observed, and there were no apparent signs of screw loosening.

The long-term outcomes of surgical treatment for spinal stenosis have been reported in a few studies. The Maine Lumbar Spine Study reported on the outcomes of a mixed cohort of spinal stenosis patients with and without de-

TABLE 3. Data regarding the index and adjacent-level disc height as to the overall lumbar lordosis

Patient No.	Index Level Disc Height (L4–5)	Adjacent-Level Disc Height (L3–4)	Adjacent-Level Disc Height (L5–S1)	Overall Lumbar Lordosis
1	8	7	11	60
2	13	12	12	71
3	12	12	10	63
4	6	12	8	71
5	12	14	11	64
6	15	12	15	63
7	12	14	6	63
8	9	9	11	51
9	7	14	12	61
Average	10.4	11.7	10.6	63

Disc height values are expressed as millimeters and lumbar lordosis as degrees.

generative spondylolisthesis. They found that the initial benefits of surgery during the 4-year follow-up narrowed by 10 years.⁴ The Spine Patient Outcomes Research Trial (SPORT) compared the long-term outcomes of surgical and nonsurgical treatment for lumbar degenerative spondylolisthesis. They reported a persistent advantage for surgery over the nonsurgical treatment in all outcome measures after an 8-year follow-up period.¹ Our study demonstrates that decompression and posterior arthroplasty with the TOPS System can achieve significant clinical improvement and maintain these improvements over an 11-year follow-up period.

One of the main concerns of posterior arthroplasty systems is screw loosening. In fusion surgery, screws withstand loads and peak moments for a short period of time until fusion is achieved and then the healed bone bears most of the dynamic load. Contrary to fusion surgery, in posterior arthroplasty systems, the pedicle screws must withstand loads and peak moments for an unlimited period. This cyclic loading can produce screw loosening.¹⁴ Our study demonstrated that in 11 years of follow-up there was no screw loosening or breakage. This is probably due to the unique TOPS design. As opposed to the classic fusion design in which a vertical rod unites 2 pedicle screws of adjacent vertebrae, in the TOPS System a dual horizontal crossbar configuration attaches 2 pedicle screws on the same vertebra. This structure diminishes peak moments by more equally dividing loads across all 4 pedicle screws and by that decrease the chance for loosening at the bone-screw interface.¹⁰ The second unique advantage of the TOPS System is its wide range of motion in all planes. This allows the system to share the loads with the intervertebral disc and the ligaments, decreasing the loads on the screws and on the screw-bone interface.

The advantages of the TOPS device are supported by in vitro cadaveric studies that have compared the peak moments between the TOPS apparatus and the Dynesys System (Zimmer).^{10,18} One study concluded that the peak moments on the TOPS pedicle screws were far lower and more equally distributed than in the Dynesys System. The moment on the screw heads was thus reduced by 36% and 46% in flexion/extension and lateral bending, respectively.

To achieve better bone integration of the TOPS System

pedicle screws, and by that to avoid loosening, the pedicle screws are blasted with calcium phosphate particles, which are later detached, leaving a roughened surface that enhances osseointegration.¹⁰

One of the problems of decompression and fusion surgery is adjacent-segment disease. Adjacent-segment disease can be radiographic or symptomatic.⁷ Adjacent-segment disease may be the result of an increased stress on the motion segments bordering the fused segment. This additional stress accelerates the degeneration of these adjacent segments, as demonstrated in many studies.^{3,12} The rationale behind a posterior motion-preservation system is that preserving motion at the stabilized level prevents degeneration of the adjacent segment.^{14,16}

Although our study demonstrated that the TOPS System maintains motion at the operated segment, the lack of a control group and the cohort size do not allow us to draw conclusions regarding the rate of adjacent-segment disease between posterior arthroplasty and fusion surgery. Currently, there is an FDA prospective study that is comparing the TOPS System to transforaminal lumbar interbody fusion (ClinicalTrials.gov Identifier: NCT03012776) and might give an answer to this question.

With an overall annual incidence of 2.5% for surgery for adjacent-segment disease and predicted 10-year prevalence of 22.2% of further surgery for adjacent-segment disease after lumbar arthrodesis,^{1,13} our data indicate that the TOPS System may reduce the rate of adjacent-level disease, although it cannot stop the normal aging of the spine.

With a small number of patients there is also a potential for selection bias, although we do believe that the study's inclusion and exclusion criteria represent typical patients with spinal stenosis and degenerative spondylolisthesis.

Conclusions

The results of this 11-year follow-up study demonstrate that in patients with spinal stenosis and degenerative spondylolisthesis, wide decompression and implantation of the TOPS System maintain clinical improvement and radiological stability. The TOPS System preserves motion at the instrumented level.

References

1. Abdu WA, Sacks OA, Tosteson ANA, Zhao W, Tosteson TD, Morgan TS, et al: Long-term results of surgery compared with nonoperative treatment for lumbar degenerative spondylolisthesis in the Spine Patient Outcomes Research Trial (SPORT). **Spine (Phila Pa 1976)** **43**:1619–1630, 2018
2. Anekstein Y, Floman Y, Smorgick Y, Rand N, Millgram M, Mirovsky Y: Seven years follow-up for total lumbar facet joint replacement (TOPS) in the management of lumbar spinal stenosis and degenerative spondylolisthesis. **Eur Spine J** **24**:2306–2314, 2015
3. Aota Y, Kumano K, Hirabayashi S: Postfusion instability at the adjacent segments after rigid pedicle screw fixation for degenerative lumbar spinal disorders. **J Spinal Disord** **8**:464–473, 1995
4. Atlas SJ, Keller RB, Wu YA, Deyo RA, Singer DE: Long-term outcomes of surgical and nonsurgical management of lumbar spinal stenosis: 8 to 10 year results from the Maine lumbar spine study. **Spine (Phila Pa 1976)** **30**:936–943, 2005
5. Försth P, Ólafsson G, Carlsson T, Frost A, Borgström F, Fritzell P, et al: A randomized, controlled trial of fusion surgery for lumbar spinal stenosis. **N Engl J Med** **374**:1413–1423, 2016
6. Ghogawala Z, Dziura J, Butler WE, Dai F, Terrin N, Magge SN, et al: Laminectomy plus fusion versus laminectomy alone for lumbar spondylolisthesis. **N Engl J Med** **374**:1424–1434, 2016
7. Harrop JS, Youssef JA, Maltenfort M, Vorwald P, Jabbour P, Bono CM, et al: Lumbar adjacent segment degeneration and disease after arthrodesis and total disc arthroplasty. **Spine (Phila Pa 1976)** **33**:1701–1707, 2008
8. Herkowitz HN, Kurz LT: Degenerative lumbar spondylolisthesis with spinal stenosis. A prospective study comparing decompression with decompression and intertransverse process arthrodesis. **J Bone Joint Surg Am** **73**:802–808, 1991
9. McAfee P, Khoo LT, Pimenta L, Capuccino A, Sengoz A, Coric D, et al: Treatment of lumbar spinal stenosis with a total posterior arthroplasty prosthesis: implant description, surgical technique, and a prospective report on 29 patients. **Neurosurg Focus** **22**(1):E13, 2007
10. Meyers K, Tauber M, Sudin Y, Fleischer S, Arnin U, Girardi F, et al: Use of instrumented pedicle screws to evaluate load sharing in posterior dynamic stabilization systems. **Spine J** **8**:926–932, 2008
11. Pfirrmann CW, Metzendorf A, Elfering A, Hodler J, Boos N: Effect of aging and degeneration on disc volume and shape: a quantitative study in asymptomatic volunteers. **J Orthop Res** **24**:1086–1094, 2006
12. Schlegel JD, Smith JA, Schleusener RL: Lumbar motion segment pathology adjacent to thoracolumbar, lumbar, and lumbosacral fusions. **Spine (Phila Pa 1976)** **21**:970–981, 1996
13. Sears WR, Sergides IG, Kazemi N, Smith M, White GJ, Osburg B: Incidence and prevalence of surgery at segments adjacent to a previous posterior lumbar arthrodesis. **Spine J** **11**:11–20, 2011
14. Stoll TM, Dubois G, Schwarzenbach O: The dynamic neutralization system for the spine: a multi-center study of a novel non-fusion system. **Eur Spine J** **11** (Suppl 2):S170–S178, 2002
15. Weinstein JN, Lurie JD, Tosteson TD, Hanscom B, Tosteson AN, Blood EA, et al: Surgical versus nonsurgical treatment for lumbar degenerative spondylolisthesis. **N Engl J Med** **356**:2257–2270, 2007
16. Wild A, Jaeger M, Bushe C, Raab P, Krauspe R: Biomechanical analysis of Graf's dynamic spine stabilisation system ex vivo. **Biomed Tech (Berl)** **46**:290–294, 2001
17. Wilke HJ, Schmidt H, Werner K, Schmölz W, Drumm J: Biomechanical evaluation of a new total posterior-element replacement system. **Spine (Phila Pa 1976)** **31**:2790–2797, 2006
18. Wright T, Tauber M, Meyers K, Sudin Y, Fleischer S, Arnin U, et al: The biomechanics of posterior motion preservation systems. **Spine J** **5**:S143–S144, 2005

Disclosures

The TOPS device (Premia Spine) that is the subject of this manuscript is being evaluated as part of an ongoing FDA-approved investigational protocol or corresponding national protocol. Dr. Floman has an ownership stake in Premia Spine. Dr. Anekstein is a consultant for Premia Spine.

Author Contributions

Conception and design: Smorgick, Mirovsky, Anekstein. Acquisition of data: Smorgick, Anekstein. Analysis and interpretation of data: Smorgick. Drafting the article: Floman, Millgram, Anekstein. Critically revising the article: Rand. Reviewed submitted version of manuscript: Floman, Millgram, Anekstein. Administrative/technical/material support: Mirovsky.

Supplemental Information

Previous Presentations

The basic contents of this paper were presented at the 19th annual meeting of the Israel Spine Society, April 25–28, 2018, Eilat.

Correspondence

Yossi Smorgick: Yitzhak Shamir Medical Center, Zerifin, Israel. ysmorgick@gmail.com.